



ELSEVIER



## Effect of chronic intake of arsenic-contaminated water on liver

D.N. Guha Mazumder\*

*Institute of Post Graduate Medical Education and Research, Kolkata-700 020, India*

Received 17 March 2004; accepted 31 August 2004

Available online 12 April 2005

### Abstract

The hepatotoxic effect of arsenic when used in therapeutic dose has long been recognized. We described the nature and degree of liver involvement and its pathogenesis due to prolonged drinking of arsenic-contaminated water in West Bengal, India. From hospital-based studies on 248 cases of arsenicosis, hepatomegaly was found in 190 patients (76.6%). Noncirrhotic portal fibrosis was the predominant lesions in 63 out of 69 cases who underwent liver biopsy. The portal fibrosis was characterized by expansion of portal zones with streaky fibrosis, a few of which contained leash of vessels. However, portal hypertension was found in smaller number of cases.

A cross-sectional epidemiological study was carried out on 7683 people residing in arsenic-affected districts of West Bengal. Out of these, 3467 and 4216 people consumed water-containing arsenic below and above 0.05 mg/l, respectively. Prevalence of hepatomegaly was significantly higher in arsenic-exposed people (10.2%) compared to controls (2.99%,  $P < 0.001$ ). The incidence of hepatomegaly was found to have a linear relationship proportionate to increasing exposure of arsenic in drinking water in both sexes ( $P < 0.001$ ).

In an experimental study, BALB/C mice were given water contaminated with arsenic (3.2 mg/l) ad libitum for 15 months, the animals being sacrificed at 3-month intervals. We observed progressive reduction of hepatic glutathione and enzymes of anti-oxidative defense system associated with lipid peroxidation. Liver histology showed fatty infiltration at 12 months and hepatic fibrosis at 15 months.

Our studies show that prolong drinking of arsenic-contaminated water is associated with hepatomegaly. Predominant lesion of hepatic fibrosis appears to be caused by arsenic induced oxystress.

© 2005 Published by Elsevier Inc.

**Keywords:** Arsenic; Oxystress; Non cirrhotic portal fibrosis; Lipid peroxidation

Chronic exposure to inorganic arsenic has been reported to be associated with chronic changes in the liver. Development of ascites has been reported in patients taking liquor arsenic in therapeutic doses for prolonged periods (Bang, 1774; Hutchinson, 1895). Cases of cirrhosis of liver resulting from continued use of Fowler's solution containing potassium arsenite have also been described (Franklin et al., 1950). However, when liver biopsies of 44 psoriatic patients receiving potassium arsenate and 37 similar patients receiving no drug were compared, no histological differ-

ences were found (Zachariae et al., 1974). Portal hypertension without signs of cirrhosis of liver has subsequently been reported following chronic arsenic medication, mostly as Fowler's solution (Huet et al., 1975; Morris et al., 1974; Neale and Azzopardi, 1971; Nevens et al., 1990; Szuler et al., 1979; Viallet et al., 1972). Some of those patients also had typical skin manifestations. Drinking of arsenic-contaminated water was first suspected to cause noncirrhotic portal hypertension in two patients from Chandigarh (Dutta et al., 1979).

Though chronic arsenic toxicity due to drinking of arsenic-contaminated water has been reported from many countries, reports of large number of affected people in West Bengal, India, and Bangladesh are unprecedented. In West Bengal, India, arsenic-contaminated ground water has been reported in 777 villages of eight districts. It is suspected that about 6 million people are exposed to arsenic-contaminated

\* Department of Medicine and Gastroenterology (Retd.), Member, Arsenic Task Force (Core Committee), Government of West Bengal., 37/C, Block "B", New Alipore, Kolkata-700 053, India. Fax: +91 33 2475 1799.

E-mail address: [dngm@apexmail.com](mailto:dngm@apexmail.com).

URL: [www.arsenichealthindia.org](http://www.arsenichealthindia.org).

drinking water (As level > 0.05 mg/l) in those 8 districts (UNICEF, 1998).

A large number of patients suffering from chronic arsenic toxicity due to drinking of arsenic-contaminated tube well water have been attending our institute since 1983. This led us to carry out a systematic study on the problem of liver affection caused by chronic intake of arsenic through drinking water. Some results of our study have been published previously (Guha Mazumder et al., 1988, 1997, 1998a). The current presentation is a compilation of our various studies between 1985 till date.

## Clinical study

A total of 248 consecutive patients with evidence of chronic arsenic toxicity attending our hospital were studied. The inclusion criteria were as follows: typical raindrop pigmentation and/or depigmentation of skin of body and limbs, thickening of palm and soles with or without nodules characteristic of chronic arsenic toxicity, and arsenic level above permissible limit (>0.05 mg/l) in the water consumed by these people. The exclusion criteria were past history of malaria or kala-azar, prolong intake of any hepatotoxic drug, chronic alcohol intake, hematological disease, and cardiovascular and metabolic disease (Santra et al., 1999). The arsenic-contaminated water (0.05–3.4 mg/l) which the subjects drank was drawn by hand pump from subsoil water at varying depths. The patient population also included 20 cases from southern Calcutta who took water containing high quantities of arsenic (5.05–14.2 mg/l) due to contamination of subsoil water by the waste of a factory manufacturing Paris green (copper acetoarsenite). None of these patients gave any history of taking arsenic-contaminated food. The duration of intake of contaminated water usually varied from 1 to 15 years, but in some cases it was life-long. Thorough clinical examination was carried out in all the cases. Detailed investigations including liver function test, viral markers, and endoscopy were carried out on 93 cases that could be admitted in the hospital. Liver biopsy was carried out on 69 of these patients who gave consent. The degree of portal fibrosis was graded as: grade I, mild fibrosis producing expansion of portal zone; grade II, expansion of portal zone with thin fibrous extension producing septa; grade III, moderate fibrosis in the portal zone with thick septa; and grade IV, dense fibrosis within the liver with a tendency to pseudolobulation (Guha Mazumder et al., 1988). Arsenic content in the liver of 29 cases was estimated by neutron activation analysis.

## Results

The 248 patients included 193 men, with mean (SD) age of 32.5 (13.4) years. Results of liver function tests

done in 93 patients with firm hepatomegaly showed elevated ALT (>40 IU/l), AST (>40 IU/l), and alkaline phosphatase ALP (>400 IU/l) in 24 (25.8%), 57 (61.3%), and 27 (29.0%) cases, respectively. Serum globulin level was found high (>3.5 g/dl) in 19 (20.7%) cases. Liver histology showed portal fibrosis in 63 (91.3%) cases, cirrhosis in 2 cases (2.9%), and normal picture in 4 (5.8%) cases. Sera of the two patients with cirrhosis were tested positive for HBsAg. The portal fibrosis was characterized by expansion of portal zones of varying degree. Fibrous extension from the portal tracts into the liver lobules producing septa was found in some cases (Fig. 1). At some regions, the expanded portal zone contained a leash of vessels replacing the portal vein branches (Fig. 2). The degree of fibrosis in the liver was mild in most patients (grade I in 34 [53.9%], grade II in 19 [30.2%]); moderate to severe fibrosis was observed in only a few cases (grade III in 6 [9.5%] and grade IV in 4 [6.3%]). Though incidence of NCPF was found in significant number of cases, evidence of portal hypertension and splenomegaly was found in smaller number of cases. The maximum arsenic content in the liver was 6 mg/kg (mean 1.46 [0.42]; control 0.16 [0.04];  $P < 0.001$ ), it was undetected in 6 of 29 samples. The arsenic content of liver tissue did not correlate with the degree of hepatic fibrosis or with the arsenic content of the water consumed (cf. Table 1).

## Discussion

The high incidence of liver involvement due to drinking of arsenic-contaminated water has not been reported previously. Although some reports of liver damage caused by chronic arsenic toxicity by intake of medicines were available in the literature earlier (Franklin et al., 1950; Hutchinson, 1895; Rosenberg, 1974), few reports emphasized the lesion to be noncirrhotic. The report of 8 cases (Nevens et al., 1990) with a review of

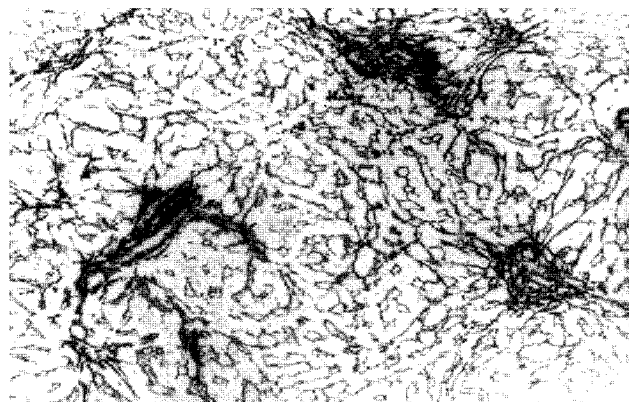


Fig. 1. Liver histology of a patient of chronic arsenic toxicity showing expansion of portal zone with streaky fibrosis (Reticulin  $\times 200$ ).

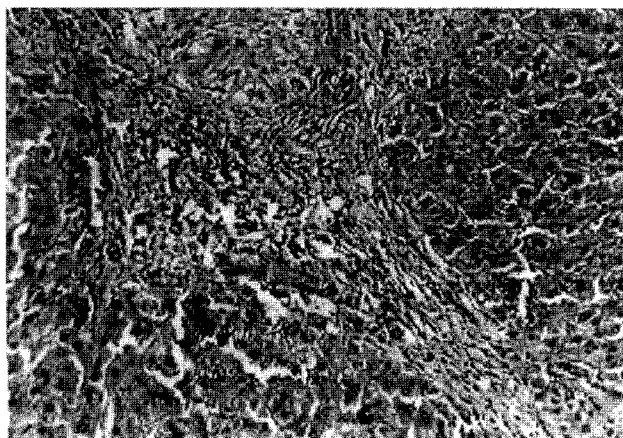


Fig. 2. Severe fibrosis of liver with expanded portal zone containing leash of vessels. Non cirrhotic portal fibrosis in a patient of chronic arsenic toxicity (H&E,  $\times 200$ ).

15 cases from the literature (Chainuvati and Viranuvatti, 1979; Dutta, 1976; Dutta et al., 1979; Gowlishaw et al., 1979; Huet et al., 1975; Morris et al., 1974; Neale and Azzopardi, 1971) highlights that noncirrhotic portal hypertension does occur in chronic arsenic toxicity. However, the incidence of portal fibrosis and that of portal hypertension associated with drinking of arsenic-contaminated water are not available in the literature. Ours was the first report to highlight that hepatomegaly occurs in a very high percentage (77%) of cases of chronic arsenicosis and the predominant (92%) histolog-

ical finding was portal fibrosis. However, portal fibrosis was found to be milder in the majority of the cases. Further, portal hypertension occurred in a smaller number of cases.

### Epidemiological study

To determine the prevalence of liver involvement associated with arsenic, a cross-sectional study was conducted in one of the most affected districts of West Bengal, the South 24 Pargans (Fig. 3) (Guha Mazumder et al., 1998b). A total of 7818 individuals participated in the drinking water study. Water arsenic levels were obtained from 7683 (4093 females and 3590 males) who constituted the study subjects. Each participant was asked questions about their various symptoms, socioeconomic status, their dietary habit, addiction, past history of major illness, and history of parasitic infestation. A thorough clinical examination of each participant was carried out taking special care to detect skin pigmentation and keratosis and enlargement of liver. Persons who had liver enlargement were further inquired regarding any past history of jaundice, parasite expulsion, history of taking alcohol or other hepatotoxic drug. Blood samples from willing participants having hepatomegaly were collected for liver function tests like analysis of serum protein, alanine amino transferase (ALT), and serodiagnostic tests like amoebic serology for *Entamoeba histolytica* (by

Table 1

Relationship between the amount of arsenic ingested by patients, its level in various body tissues, and the severity of hepatic lesions

Arsenic level (mg/kg) in							Liver lesions <sup>b</sup>			
Patient	Age (years)/ Sex <sup>a</sup>	Arsenic concentration in tube well water (mg/l)	Duration of water intake (year)	Hair	Nail	Liver (dry weight)	Fibrosis in portal zone	Enlargement of portal zone	Tendency to pseudolobule formation	Multiple vascular channel in portal tract
1	43/F	0.75	10 <sup>c</sup>	7.5	24	ND <sup>d</sup>	++++ <sup>e</sup>			
2	26/F	2	4	13.3	66	1.5	+	none	none	+
3	25/F	2	4	1.4	40	1	++	+	none	+
4	23/F	2	4	7.1	57	0.5	++++	+	+	+
5	47/M	2	1 <sup>c</sup>	7.7	27	3	+	+	none	+
6	22/M	2	1	3.8	16	1.5	++	+	+	+
7	36/M	2	4 <sup>c</sup>	20	41	ND	++	+	none	+
8	31/M	2	4 <sup>c</sup>	7.4	31	1.5	+	+	+	+
9	30/M	2	4	ND	24	1	+++	+	++	+
10	30/M	0.5	20 <sup>c</sup>	4.7	26	ND	++++	+	+	+
11	25/M	0.22	1	7.1	ND	2	+	none	none	none
12	40/F	2	1	6	29	6	+++	+	+	+
13	18/M	2	1	3.6	27	3	+++	+	none	+
Control values		< 0.05 (n = 96)		0.15 ± 0.35 (n = 5); P < 0.001	0.34 ± 0.25 (n = 5); P < 0.001	0.16 ± 0.04 (n = 5); P < 0.01				

<sup>a</sup> M = male; F = Female.

<sup>b</sup> Grading of fibrosis: + to ++++.

<sup>c</sup> Presence of portal hypertension.

<sup>d</sup> ND = not detectable.

<sup>e</sup> Unsatisfactory liver biopsy showing scar tissue and fragmented liver lobule. The patient had gross splenomegaly and a history of hematemesis.

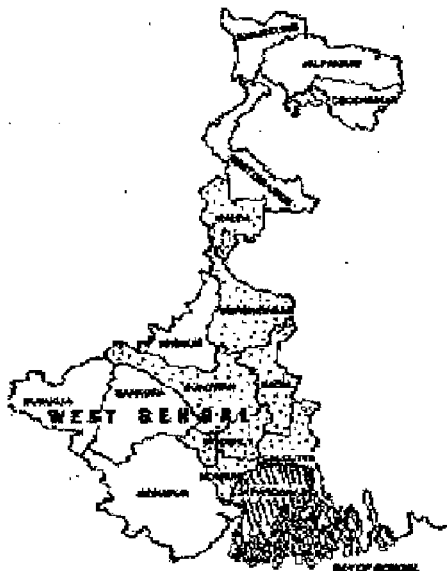


Fig. 3. Map of West Bengal (India) showing different arsenic affected districts. Epidemiological study was done in South 24 Pargans (shaded area).

commercially available EIA kit) HBsAg by ELISA and anti-HCV by 3rd generation ELISA kit (Hepanostica, Organon Technica, Belgium).

## Results

From an epidemiological study, hepatomegaly was found in 104 people out of 3467 people (2.99%) drinking water-containing arsenic less than 0.05 mg/l while in 431 people drinking water-containing arsenic above this level (10.21%,  $P < 0.001$ ). Thus, enlargement of liver was found in much higher number of people drinking As-contaminated water compared to control population. History of chronic alcohol intake, past history of jaundice, and round worm infection were found among 5 (4.8%), 26 (25%), and 29 (27.8%) participants in the control population while in 19 (4.4%), 55 (12.76%), and 132 (30.62%) subjects in the As-exposed group, respectively, with hepatomegaly. Blood could be tested for viral makers among 26 people belonging to the low exposure group and 143 people to the high exposure group. HBsAg was found to be positive in 2 (7.69%) in the former group and 7 (4.82%) in the later group. Anti-HCV was negative in all cases belonging to both groups. Further, anti-amoebic antibody titer was found to be high ( $>1:125$ ) in the blood of 6 (26.08%) out of 23 participants of the former group and 25 (25.25%) out of 99 participants of the later group. Thus, the significantly high incidence of hepatomegaly observed in the As-exposed group compared to control population could not be incremented to any of the common etiological factors associated with hepatomegaly in the tropics. Of the various parameters of

liver function tests, serum albumin, globulin, and ALT levels could be tested in 124 people, drinking high As in water ( $>0.05$  mg/l), having hepatomegaly without any known etiological factor (i.e., history of jaundice, HBsAg and HCV seropositivity, and elevated titer of amoebic serology). Abnormal serum albumin level ( $<3.0$  g/dl) was found in 4 cases (3.22%) and globulin ( $>3.5$  g/dl) was found in 17 cases (13.71%), respectively. Elevation of serum ALT ( $>40$  U/l) was found in 27 cases (21.77%) (Guha Mazumder et al., 2001).

Prevalence of hepatomegaly corresponding to various As dose exposure among male and females is plotted in Fig. 4. The incidence of hepatomegaly was found to have a linear relationship proportionate to increasing exposure of As in drinking water in both sexes ( $P < 0.001$ ). The prevalence of hepatomegaly among females was 3.46% in the lower exposure category ( $<0.05$  mg/l), while its incidence was 17.83% in the highest exposure category ( $\geq 0.8$  mg/l). A stronger trend appeared in males, the prevalence increased from 2.62% in the lowest category to 28.81% in the highest exposure category. The prevalence was greater among males than females (Guha Mazumder et al., 2001).

## Discussions

The high incidence of hepatomegaly among the arsenic-exposed population compared to control group appears to be arsenic related as there was no preponderance of any of the etiological factors for hepatomegaly in the tropics (e.g., history of alcohol intake, jaundice, round worm infection, HBV, HCV, and amoebic seropositivity) (Guha Mazumder et al., 1984) in any of the two groups compared. Further, the prevalence of hepatomegaly was found to have a linear relationship proportionate to increasing exposure of arsenic in drinking water in both sexes ( $P < 0.001$ ). Liver enlargement has also been reported in cases of chronic arsenic toxicity due to drinking arsenic-contaminated water

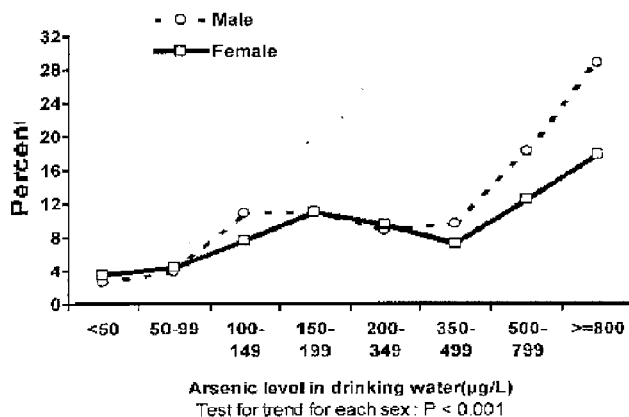


Fig. 4. Prevalence of liver enlargement per 100 for males and females in relation to arsenic exposure in West Bengal.

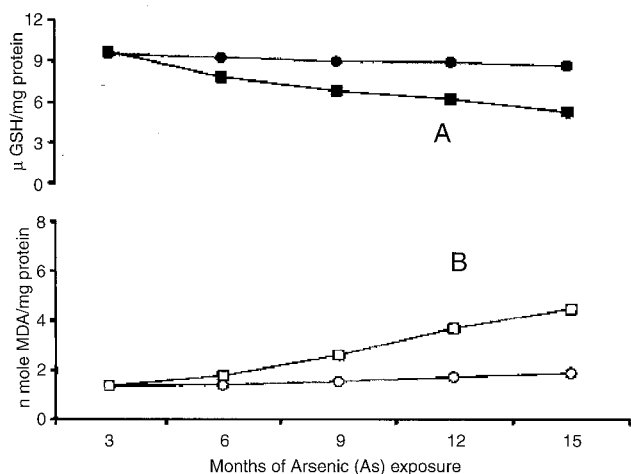


Fig. 5. Relationship between hepatic GSH content and MDA concentration, a marker of lipid peroxidation, in mice exposed to chronic arsenic toxicity. Panel A shows the time-related reduction of hepatic GSH content in the arsenic-fed mice (■) compared to control (●). Panel B shows hepatic MDA levels with time in arsenic-fed mice (□) compared to control (○).

by workers from other countries (Ahmad et al., 1997, 1999; Ma et al., 1999).

### Experimental study

Oxidative damage is thought to underlie several chronic liver diseases that are associated with fibrosis. Oxidative stress can result in the peroxidative damage of the major cellular components including amino acids, carbohydrates, lipids, proteins, and nucleic acids (Bellomo and Orrenius, 1985; Sies, 1985). Lipid peroxidation has been proposed as the mechanism of hepatic fibrosis due to excess iron (Bacon et al., 1983) or copper deposition in experimental animals. Based on these studies, we hypothesized that lipid peroxidation-mediated membrane damage, presumptively due to oxidative stress and reduced enzymatic antioxidant defense, may be an important mechanism of the hepatic fibrosis that results from chronic arsenic toxicity. To test this hypothesis, we utilized a murine model in which hepatic fibrosis was induced by feeding arsenic-contaminated water for 15 months.

Male BALB/c mice were given drinking water contaminated with arsenic (3.2 mg/l) or arsenic-free (<0.01 mg/l, control) ad libitum. Mice were sacrificed at 3, 6, 9, 12, and 15 months for examination of hepatic histology and assay of hepatic-reduced glutathione content, lipid peroxidation, enzymes of the antioxidant defense system, and membrane-bound sodium/potassium ATPase ( $\text{Na}^+/\text{K}^+$  ATPase).

### Results

After 12 months of arsenic feeding, the liver weights increased significantly as did serum aspartate amino trans-

ferase and alanine amino transferase. After 6 months of arsenic feeding, hepatic glutathione and the enzymes glucose-6-phosphate dehydrogenase and glutathione peroxidase were significantly lower than those of the control group. Hepatic catalase activity was significantly reduced at 9 months in the arsenic-fed group, while glutathione-S-transferase and glutathione reductase activities were also significantly reduced at 12 and 15 months. Plasma membrane  $\text{Na}^+/\text{K}^+$  ATPase activity was reduced after 6 months while lipid peroxidation increased significantly after 6 months of arsenic feeding. As shown in Fig. 5, the lipid peroxidation increased with time and was inversely related with hepatic GSH content. Liver histology remained normal for the first 9 months, but showed fatty infiltration after 12 months of arsenic feeding. Histologic evidence of fibrosis was observed after 15 months (Fig. 6) (Santra et al., 2000).

### Discussions

Inorganic arsenic increases the rate of formation of active oxygen species, including superoxide anion radicals ( $\text{O}_2^-$ ), hydroxyl (OH) radical through a chain reaction (Yamanaka et al., 1989a, 1989b, 1990). The mechanism of arsenic toxicity to individual cell type has historically centered around the inhibitory effects on cellular respiration at the level of mitochondria (Fluharty and Sanadi, 1960, 1962). Disruption of oxidative phosphorylation and concomitant decrease in the cellular levels of ATP (Chen et al., 1986) are thought to be important central events of arsenic-induced toxicity evoking increased production of hydrogen peroxide. These effects could cause formation of reactive oxygen species resulting in oxidative stress (NRC, 1999).

The increased lipid peroxidation and plasma membrane damage, as shown by a progressive reduction of  $\text{Na}^+/\text{K}^+$  ATPase activity in mice drinking arsenic-contaminated water in our study, paralleled GSH depletion of the liver.

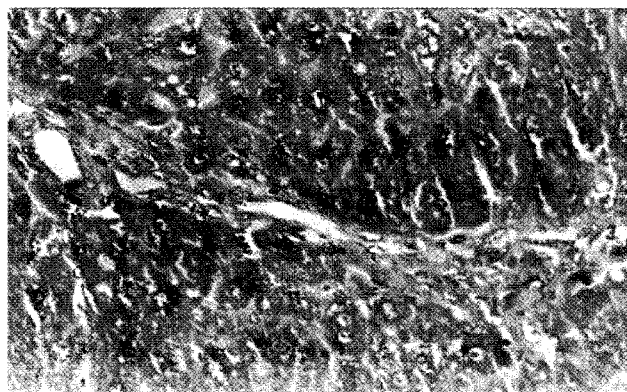


Fig. 6. Liver histology of mice exposed to arsenic for 15 months. The histology shows mature collagen deposition spreading from the portal tracts through the liver lobules (Mason Trichrome  $\times 400$ ).

GSH depletion resulted in the accumulation of free radicals that initiated lipid peroxidation resulting in biochemical damage by covalent binding to macromolecules. GSH depletion and enhanced lipid peroxidation in rat liver have also been reported in rats treated with a large dose of sodium arsenite (18.2 mg/kg body weight) (Ramos et al., 1995). Similarly, oxidative damage and peroxidation of lipid membranes have been observed with excessive hepatic iron (Bacon et al., 1983; Sokol et al., 1990), and copper deposition in experimental animals. Peroxidative breakdown of polyunsaturated fatty acids and membrane phospholipids leads to biochemical changes culminating in the inactivation of membrane enzymes, such as  $\text{Na}^+/\text{K}^+$  ATPase, that may lead to alteration of ion transport and cellular water content, eventually leading to cell death. Several studies have also implicated lipid peroxidation in the pathogenesis of hepatic fibrogenesis, which was seen as a relatively late outcome of chronic arsenic consumption in our study. Considered together, these observations suggest that weakening of the antioxidant defense system of the liver and consequent peroxidative damage of the lipid membranes may play a central role in the causation of liver pathology in chronic arsenic toxicity.

## Conclusions

Our studies show that prolonged drinking of arsenic-contaminated water is associated with liver enlargement. Noncirrhotic portal fibrosis appears to be the predominant lesion in the liver, though portal hypertension occurs in a small number of cases. The possible mechanism of liver fibrosis appears to be failure of anti-oxidative defense mechanism leading to membrane damage.

## Acknowledgments

The materials presented in the communication are based on studies carried out at Institute of Post Graduate Medical Education and Research, Kolkata, India, with the assistance of the following co-investigators: Mrs. N. Ghosh, A. Santra, J. Dasgupta, A. Pal, A. Ghosh, S. Sarkar, N. Chattopadhyaya, B.K. De, B.K. Roy, U.C. Ghoshal, J. Saha, A. Chatterjee, S. Dutta, S. Lahiri, S. Das, T. Das, and D. Chakraborti. The author expresses thanks to the Director of the Institute and Director of Medical Education, Govt. of West Bengal for allowing him to carry on the studies. The epidemiological study was funded by the Rajib Gandhi National Drinking Water Mission, Ministry of Rural Development, Government of India, research grants W-11046/2/496-TM II (R and D). The author thanks Mr. Biswajit Debnath, Computer Programmer, IPGME and R, and Mr. S.B. Mitra for assistance in preparation of the manuscript.

## References

- Ahmad, S.A., Bandaranayake, D., Hahn, A.W., 1997. Arsenic contamination in ground water and arsenicosis in Bangladesh. *Int. J. Environ. Health Res.* 7, 271–276.
- Ahmad, S.A., Sayed, M.H.S.U., Hadi, S.A., Faruquee, M.H., Khan, M.H., Galil, M.A., Ahmed, R., Khan, A.W., 1999. Arsenicosis in a village in Bangladesh. *Int. J. Environ. Health Res.* 9, 187–195.
- Bacon, B.R., Tavill, A.S., Brittenham, G.M., Park, C.H., Recknagel, R.O., 1983. Hepatic lipid peroxidation in vivo in rats with chronic iron overload. *J. Clin. Invest.* 71, 429–439.
- Bang, F.L., 1774. De hydrope ex ingestio arsenico observatio. *Soc. Med. Haerl. Collect.* 1, 307.
- Bellomo, G., Orrenius, S., 1985. Altered thiol and calcium homeostasis in oxidative hepatocellular injury. *Hepatology* 5, 876–882.
- Chainuvati, T., Viranuvatti, V., 1979. Idiopathic portal hypertension and chronic arsenic poisoning. *Dig. Dis. Sci.* 24, 70–73.
- Chen, B., Burt, C.T., Geroring, P.L., Fowler, B.A., London, R.E., 1986. In vivo 31-P nuclear magnetic resonance studies of arsenite induced changes in hepatic phosphate levels. *Biochem. Biophys. Res. Commun.* 139, 228–234.
- Dutta, D.V., 1976. Arsenic and non cirrhotic portal hypertension (Letter). *Lancet* 1, 433.
- Dutta, D.V., Mitra, S.K., Chhuttani, P.N., Chakravarti, R.N., 1979. Chronic oral arsenic intoxication as a possible aetiological factor in idiopathic portal hypertension (non-cirrhotic portal fibrosis) in India. *Gut* 20, 378–384.
- Fluharty, A., Sanadi, D.R., 1960. Evidence for a vicinal dithiol in oxidative phosphorylation. *Proc. Natl. Acad. Sci. U. S. A.* 46, 608–616.
- Fluharty, A., Sanadi, D.R., 1962. On the mechanism of oxidative phosphorylation IV. Mitochondrial swelling caused by arsenite in combination with 2,3-dimercaptopropanol and by cadmium ion. *Biochemistry* 1, 276–281.
- Franklin, M., Bean, W.B., Hardin, R.C., 1950. Fowler's solution as an etiological agent in cirrhosis. *Am. J. Med. Sci.* 518, 589–596.
- Gowlishaw, J.L., Pollard, E.J., Gowen, A.W., 1979. Liver disease associated with chronic arsenic ingestion. *Aust. N.Z.J. Med.* 9, 310–313.
- Guha Mazumder, D.N., Pal, A.K., Ghosh, A.K., Pal, N.C., Chatterjee, S.K., 1984. Non specific liver disease in the tropics. *J. Indian Med. Assoc.* 82, 349–353.
- Guha Mazumder, D.N., Chakraborty, A.K., Ghosh, A., Das Gupta, J., Chakraborty, D.P., Dey, S.B., Chattopadhyaya, N., 1988. Chronic arsenic toxicity from drinking tubewell water in rural west Bengal. *Bull. World Health Organ* 66, 499–504.
- Guha Mazumder, D.N., Das Gupta, J., Santra, A., Pal, A., Ghosh, A., Sarkar, S., Chattopadhyaya, N., Chakraborty, D., 1997. Non cancer effects of chronic arsenicosis with special reference to liver damage. In: Abernathy, C.O., Calderon, R.L., Chappell, W.R. (Eds.), *Arsenic Exposure and Health Effects*. Chapman & Hall, London, pp. 112–123.
- Guha Mazumder, D.N., Das Gupta, J., Santra, A., Pal, A., Ghosh, A., Sarkar, S., 1998a. Chronic arsenic toxicity in West Bengal—The worst calamity in the world. *J. Indian Med. Assoc.* 96, 4–7.
- Guha Mazumder, D.N., Haque, R., Ghosh, N., De, B.K., Santra, A., Chakraborty, D., Smith, A.H., 1998b. Arsenic levels in drinking water and the prevalence of skin lesion in West Bengal, India. *Int. J. Epidemiol.* 27, 871–877.
- Guha Mazumder, D.N., Ghose, N., De, B.K., Santra, A., Das, S., Lahiri, S., Haque, R., Smith, A.H., Chakraborty, D., 2001. Epidemiological study on various non-carcinomatous manifestations of chronic arsenic toxicity in a district of West Bengal. In: Chappell, W.R., Abernathy, C.O., Calderon, R.L. (Eds.), *Arsenic Exposure and Health Effects IV*. Elsevier Science Ltd, Oxford, pp. 153–164.
- Huet, P.M., Guillaume, E., Gote, J., Legare, A., Lavoit, P., Viallet, A., 1975. Non-cirrhotic presinusoidal portal hypertension—Association with chronic arsenical intoxication. *Gastroenterology* 68, 1270–1277.

- Hutchinson, J., 1895. Diet and therapeutics. *Arch. Surg.* 6, 389–395.
- Ma, H.Z., Xia, Y.J., Wu, K.G., Sun, T.Z., Mumford, J.L., 1999. Human exposure to arsenic and health effects in Bayingormen, Inner Mongolia. In: Abernathy, C.O., Calderon, R.L., Chappell, W.R. (Eds.), *Arsenic Exposure and Health Effects*. Elsevier Amsterdam, pp. 127–132.
- Morris, J.S., Schmid, M., Newman, S., Schever, P.G., Sherlock, S., 1974. Arsenic and non cirrhotic portal hypertension. *Gastroenterology* 66, 86–94.
- Neale, G., Azzopardi, J.G., 1971. Chronic arsenical poisoning and noncirrhotic portal hypertension—A case for diagnosis. *Br. Med. J.* 4, 725–730.
- Nevens, F., Fevery, J., Stembergen, W.V., Sciot, R., Desmet, V., De Groote, J., 1990. Arsenic and non cirrhotic portal hypertension. *J. Hepatol.* 11, 80–85.
- NRC (National Research Council), 1999. *Arsenic in Drinking Water*. National Academy Press, Washington, DC.
- Ramos, O., Carrizales, L., Yanez, L., 1995. Arsenic increased lipid peroxidation in rat tissues by a mechanism independent of glutathione levels. *Environ. Health Perspect.* 103 (Suppl. 1), 85–88.
- Rosenberg, H.G., 1974. Systemic arterial disease and chronic arsenicism in infants. *Arch. Pathol.* 97, 360–365.
- Santra, A., Das, G.J., Das Gupta, J., De, B.K., Roy, B., Guha Mazumder, D.N., 1999. Hepatic manifestations in chronic arsenic toxicity. *Indian J. Gastroenterol.* 17 (4), 152–155.
- Santra, A., Maity, A., Das, S., Lahiri, S., Chakraborty, S.K., Guha Mazumder, D.N., 2000. Hepatic damage caused by chronic arsenic toxicity in experimental animals. *Clin. Toxicol.* 38, 395–405.
- Sies, H. (Ed.), *Oxidative Stress*. Academic Press, New York.
- Sokol, R.J., Devereaux, M., Mieran, G.W., Hanbidge, K.M., Shikes, R.H., 1990. Oxidant injury to hepatic mitochondrial lipids in rats with dietary copper overload: modification by vitamin E deficiency. *Gastroenterology* 99, 1061–1071.
- Szuler, I.M., Williams, C.N., Hinmarsh, J.T., Park Dinsoy, H., 1979. Massive variceal hemorrhage secondary to presinusoidal portal hypertension due to arsenic poisoning. *Can. Med. Assoc. J.* 120, 168–171.
- UNICEF. 1998. Plan of action to combat situation assessing out of arsenic contamination in drinking water: plan to assist Government of West Bengal by UNICEF; UNICEF East India Office, Calcutta 6 p.
- Viallet, A., Guillaume, E., Gote, J., Legare, A., Lavoie, P., 1972. Presinusoidal portal hypertension following chronic arsenic administration (abstr.). *Gastroenterology* 62, 177.
- Yamanaka, K., Hasegawa, A., Sawamura, R., Okada, S., 1989. DNA strand breaks in mammalian tissues induced by methylarsenics. *Biol. Trace Elem. Res.* 21, 413–417.
- Yamanaka, K., Hasegawa, A., Sawamura, R., Okada, S., 1989. Dimethylated arsenics induce DNA strand breaks in lung via the production of active breaks in lung via the production of active oxygen in mice. *Biochem. Biophys. Res. Commun.* 165, 43–50.
- Yamanaka, K., Hoshino, M., Okamoto, M., 1990. Induction of DNA damage by dimethylarsine, a metabolite of inorganic arsenics, is for the major part likely due to its peroxy radical. *Biochem. Biophys. Res. Commun.* 168, 58–64.
- Zachariae, H., Sogaard, H., Nyfors, A., 1974. Liver biopsy in psoriatics previously treated with potassium arsenite. *Acta Derm. Venereol. (Stockh).* 54, 235–236.